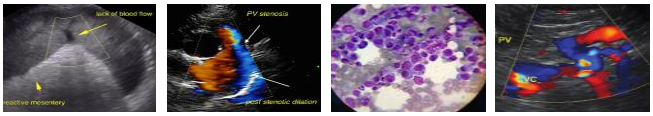

SonoPath.com
1-800-838-4268 info@sonopath.com

DATE

1/3/23

PERFORMED BY:

Dr. Meredith Swart

INTERPRETED BY

Keith Blass, DVM, MS, DACVIM (Cardiology)

PATIENT

Finnegan Ascolese

SPECIES

Feline

BREED

DSH

SEX

MN

AGE

6 y

WEIGHT

15.6 lb

HOSPITAL NAME

Swart Veterinary Imaging

REFERRING VET

Dr. Swart

PRESENTING CLINICAL SIGNS

History: New murmur. Some weight gain. Thoracic radiographs WNL.

ECHOCARDIOGRAPHIC FINDINGS

2D, M-mode, and Doppler study.

There is borderline mild left atrial dilation. The mitral valve appears normal. Left ventricular wall thickness is normal. Left ventricular internal dimensions are normal. Left ventricular systolic function is hyperdynamic. The aorta and aortic valve are normal. Right atrial and right ventricular dimensions are normal. The tricuspid valve appears normal. The pulmonary artery and pulmonic valve are normal. No heartworms are visualized. No pericardial effusion or cardiac masses are seen.

LA/Ao – 1.50
IVSd – 5.4 mm
LVPWd – 5.2 mm
LVIDd – 16.0 mm
LVIDs – 7.2 mm
FS – 55%
LVOT – 0.64 m/s
RVOT – 0.89 m/s

ASSESSMENT/RECOMMENDATIONS

This examination demonstrates borderline mild dilation of Finnegan's left atrium. This could potentially represent a normal finding, however, the presence of very mild pathologic dilation secondary to a restrictive cardiomyopathy (RCM) or atrial myopathy cannot be ruled out. As only borderline dilation is present, Finnegan's current risk for the development of clinical signs of cardiac dysfunction, such as labored breathing, collapse, and limb paralysis, appears to be low.

No reason for Finnegan's murmur is appreciated in the image set.

A recheck echocardiogram is recommended in 6-9 months, sooner if new clinical signs compatible with cardiac dysfunction develop.

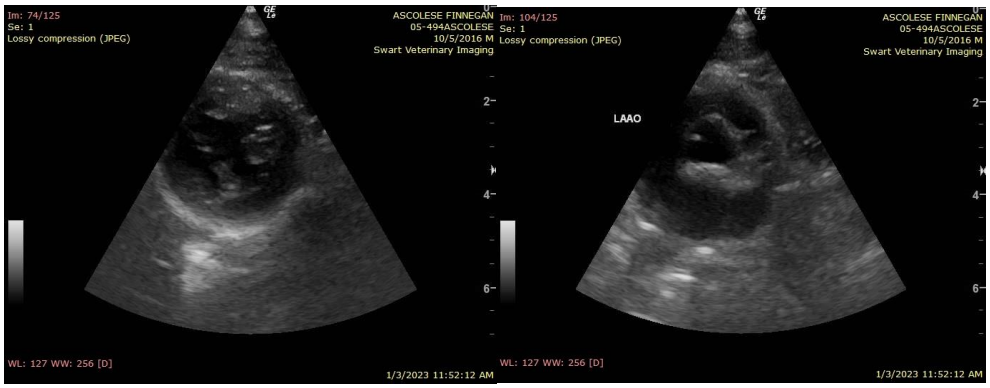

The information and recommendations provided are based on the images presented by the referring veterinarian. No evaluation can be communicated regarding pathology that was not visible in the image/video clips provided.

Thank you for this referral. If the clinical or image interpretation does not parallel your findings or

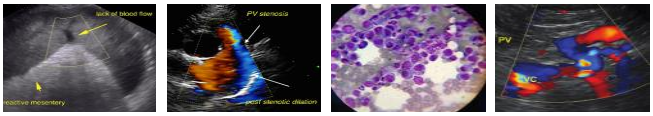

if I can be of any further assistance please contact me.

Keith Blass, DVM, MS, DACVIM (Cardiology)
KeithBlass@gmail.com
631-804-5754

DATE

1/3/23

PERFORMED BY:

Dr. Meredith Swart

INTERPRETED BY

Keith Blass, DVM, MS, DACVIM (Cardiology)

PATIENT

Finnegan Ascolese

SPECIES

Feline

BREED

DSH

SEX

MN

AGE

6 y

WEIGHT

15.6 lb

HOSPITAL NAME

Swart Veterinary Imaging

REFERRING VET

Dr. Swart